Archives of Rehabilitation Research and Clinical Translation (2025) 7, 100426

ACRM AMERICAN CONGRESS OF REHABILITATION MEDICINE

Archives of Rehabilitation Research and Clinical Translation

Archives of Rehabilitation Research and Clinical Translation 2025;7:100426

Available online at www.sciencedirect.com

CASE REPORT

Percutaneous Cryoneurolysis as a Dynamic Treatment for Spasticity: A Case Series

Clay C. Guynn, DO

Orthopaedics/Sports Medicine Deartment, Sports Medicine South of Gwinnett, Lawrenceville, GA

KEYWORDS
Case report;
Cryoneurolysis;
Rehabilitation;
Spasticity

ABSTRACT Spasticity, whether from stroke or spinal cord injury or other causes, remains challenging to treat effectively. Common spasticity treatments such as stretching, physical therapy, injection therapy, and even surgery may not result in optimal or the desired outcomes or be appropriate for all patients. Cryoneurolysis is another potential treatment option for spasticity that may have benefits over traditional spasticity treatments. In this case series, 10 patients received cryoneurolysis of specific nerves to treat either lower or upper-extremity pain, weakness, and spasticity, or a neuropathic gait in an outpatient clinic. All 10 patients experienced immediate improvements that were sustained for 1-12 months after treatment. Cryoneurolysis is a safe and effective treatment for spasticity and can allow for easy access to involved nerves.
© 2025 The Authors. Published by Elsevier Inc. on behalf of American Congress of Rehabilitation Medicine. This is an open access article under the CC BY-NC-ND license (http://creativecommons.org/licenses/by-nc-nd/4.0/).

Spasticity is a common and debilitating problem involving upper motor neuron damage to the brain motor cortex or spinal cord. Patients who have experienced a stroke, spinal cord injury, or other related conditions often seek the advice of a physical medicine and rehabilitation physician for this issue. An estimated 2.58 million adults in the United States are affected by spasticity, with ~1.07 million experiencing problematic spasticity.[1] Although management of spasticity has been done successfully for years, it can be challenging to treat; spasticity is complicated by various movement disorders and severe pain, and it is further exacerbated by other medical conditions. Common treatments are stretching, physical therapy, splinting, oral medications, injection therapy with either botulinum toxin or phenol, and surgical procedures.[2,3] Additionally, for patients who have no success or complications with these options, a baclofen pump can provide good spasticity relief without the negative cognitive effects of oral antispasticity medications such as baclofen.[4]

Another potential treatment option for spasticity is cryoneurolysis.[5] Cryoneurolysis consists of the application of cold temperatures (between −20 and −100°C) to peripheral sensory nerves to create second-degree injury (Wallerian degeneration) without damaging the surrounding tissues or

List of abbreviations: DNB, diagnostic nerve block; MAS, modified Ashworth scale; TUG, timed up and go.

This research did not receive any specific grant from funding agencies in the public, commercial, or not-for-profit sectors. Manuscript editing and submission support were provided by MedThinkSciCom, with funding from Pacira BioSciences, Inc.
Cite this article as: Arch Rehabil Res Clin Transl. 2025;000:100426

https://doi.org/10.1016/j.arrct.2025.100426
2590-1095/© 2025 The Authors. Published by Elsevier Inc. on behalf of American Congress of Rehabilitation Medicine. This is an open access article under the CC BY-NC-ND license (http://creativecommons.org/licenses/by-nc-nd/4.0/).

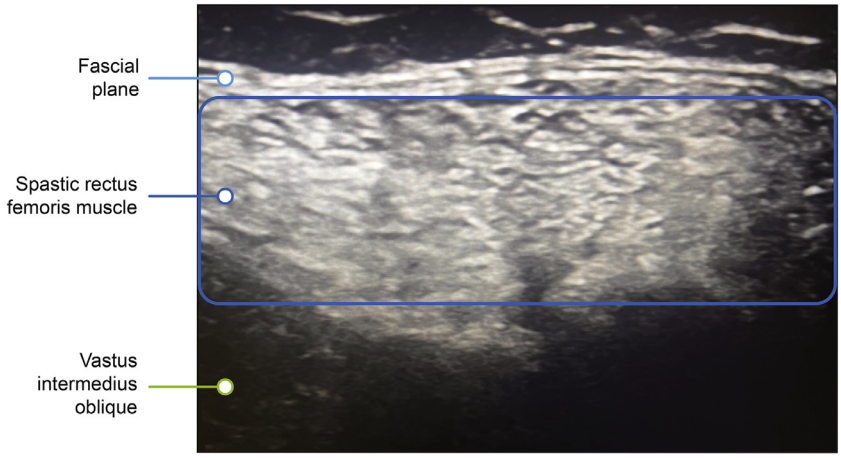

Fig 1 Lower extremity ultrasound image shows a spastic rectus femoris muscle (highlighted in dark blue rectangle and by the dark blue dot). The vastus intermedius oblique (green dot) and fascial plane (light blue dot) are also visible. Spastic muscle is typically more hyperechoic than traditional muscular fibers on ultrasound images.

permanently damaging the nerves.[6] Schwann cells form scaffolding for nerve regeneration, which occurs at a rate of 1-2 mm per day, to reinnervate the muscle or sensory receptor.[6] This gradual process results in prolonged efficacy, with some previous research suggesting the effects of cryoneurolysis can persist for months.[7] Potential adverse effects associated with cryoneurolysis include bleeding, bruising, redness, infection at the injection site, development of an insensate area near the treated nerve, hyper- or hypopigmentation, and alopecia.[6] Patients with cryoglobulinemia, cold urticaria, and Raynaud's phenomenon are contraindicated for cryoneurolysis.[6] A diagnostic nerve block (DNB) with a local anesthetic (eg, 2% lidocaine) is typically used before cryoneurolysis to predict the potential effectiveness of cryoneurolysis, given DNBs result in similar but transient effects that last for a few hours.[5,8-10] Here, 10 cases of treating spasticity successfully with cryoneurolysis using a device currently being studied for the treatment of pain associated with spasticity that is indicated for blocking pain to a specific site in peripheral nervous tissue where cold is applied are described.

Methods

The DNB was performed with 1 mL of 2% lidocaine on the day preceding the cryoneurolysis procedure. Cryoneurolysis was performed using the iovera° device, a battery-powered, portable handheld device with a cryoprobe ranging from 0.4-0.7 mm in diameter that uses compressed nitrous oxide to cool single-use tips.[6] The device is currently approved for tissue destruction during surgical procedures, as well as for pain relief in the peripheral nervous system. It is also effective for alleviating pain and symptoms related to knee osteoarthritis.[11] However, it is not approved for treating central nervous system tissues.[11] The portability of the device allows for use in an office setting in addition to a hospital or ambulatory surgery center.[6] Written informed consent was obtained from all patients or their caretaker for the publication of their medical information and any associated images included in this article. Ethical approval was also obtained. The device that is the subject of this article has been cleared through the Premarket Notification (510(k)) process/approved through a Premarket Approval application for [state the specific indication on a separate page and attach], but not for the indications that were reported. Ultrasound images of lower extremity muscles are shown before (fig 1) and after (fig 2) the cryoneurolysis procedure, upper muscle extremity during the cryoneurolysis procedure (fig 3), and the ice ball after the cryoneurolysis procedure (fig 4) are included.

Case 1

A 63-year-old man was referred to the outpatient clinic from another orthopedic clinic because of pain, weakness, spasticity, and falls in his right lower extremity, which developed after he contracted COVID-19. Before becoming ill, the patient reported having no physical symptoms. The patient had previously been evaluated by a neurologist and that evaluation was negative for other causative factors including neurodegenerative disorders, central nervous system cancer, and genetic causes. Testing included central nervous system contrast scanning, genetic testing, and laboratory testing for relevant diseases. The patient's working diagnosis was idiopathic spasticity secondary to COVID-19. The clinical evaluation revealed a neuropathic, spastic gait with internal rotation of the foot that worsened in swing phase, weak dorsiflexors at 3/5, and higher reflexes on the involved extremity. The patient underwent ultrasound-guided cryoneurolysis of the medial gastrocnemius branch of the tibial nerve with immediate and lasting improvement in gait speed and safety. The timed up and go (TUG) test improved immediately from 9-10 seconds. The patient then received physical therapy, was given a transcutaneous electrical nerve stimulation—assisted ankle foot orthosis device, and underwent neuromuscular electrical stimulation to strengthen weak tibial anterior muscles. Three months after treatment, the patient reported strengthened fibular innervated muscles, no foot internal rotation, and improvement in gait/quality of life.

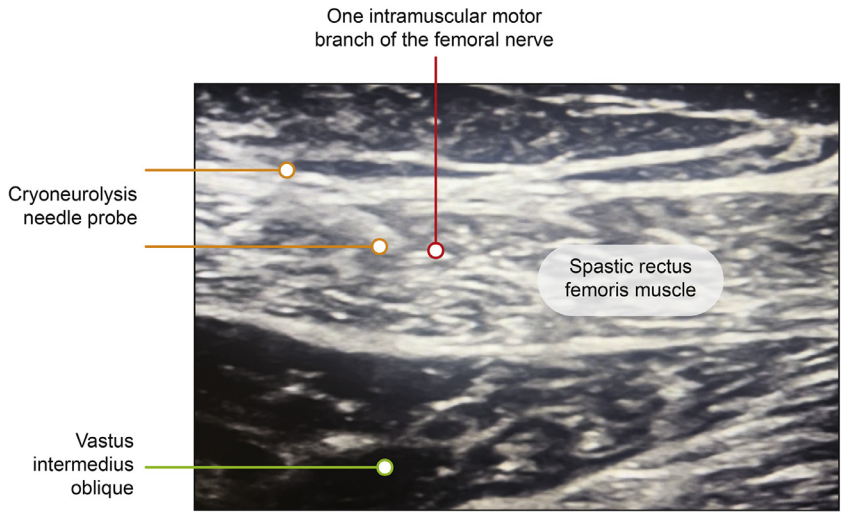

Fig 2 Lower extremity ultrasound image shows a quadriceps muscle cryoneurolysis procedure. The needle probe (orange arrows) is shown going around an intramuscular motor branch of the femoral nerve (red dot). The vastus intermedius oblique is also visible (green dot).

Case 2

A 55-year-old man with a history of stroke for 6 months presented for treatment of painful, spastic hemiparesis in his left upper extremity and associated functional decline. The patient had no prior management of the poststroke spasticity. The clinical evaluation revealed a classic spastic hemiparetic posturing of the right upper extremity with modified Ashworth scale (MAS) score of 3 in the pectoralis muscles, elbow flexors, and finger flexors. Initially, 300 U of onabotulinumtoxinA was trialed with mild improvements of 1 point on the scale without improvements in pain around the classic 6-week period, with waning results at ~3 months. After the patient's request for additional options, ultrasound-guided cryoneurolysis was performed on the medial pectoral nerve, musculocutaneous nerve, median nerve, and ulnar nerve. Immediate improvements to the MAS (1+) were sustained at the sixth week with complete resolution of pain. The patient started physical therapy, and range of motion continued to improve with sustained relief at 6 months.

Case 3

A 39-year-old woman with multiple sclerosis, who was otherwise healthy, presented to the clinic for neuropathic gait and leg "heaviness." The patient regularly used marijuana and experienced failure of prior interventions for spasticity including onabotulinumtoxinA injections and oral

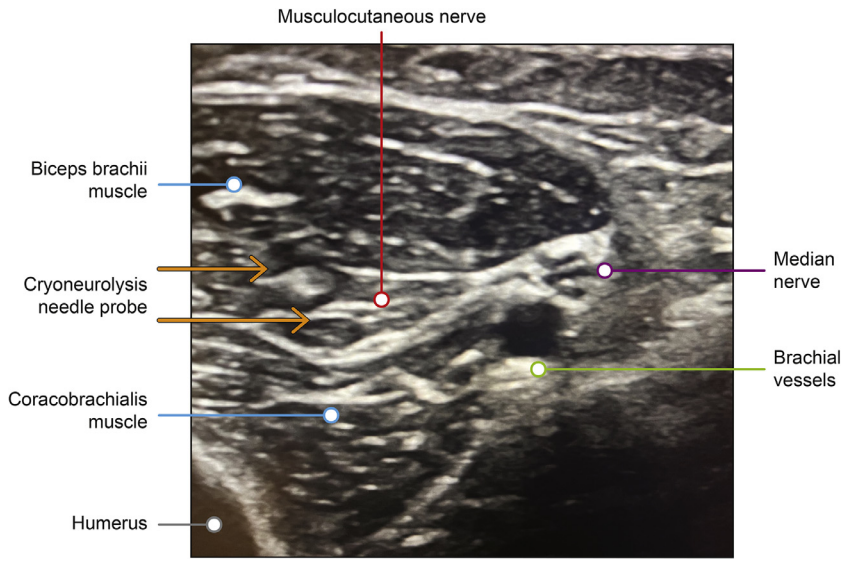

Fig 3 Upper extremity ultrasound image shows cryoneurolysis needle probe placement (orange arrows) for an intramuscular motor branch of the musculocutaneous nerve (red dot). The 2 major muscles visible in the image are the biceps brachii and the coracobrachialis (light blue dots). The humerus is also visible (gray dot). Visualization of the brachial vessels (green dot) and median nerve (purple dot) is important because in some cases they can also be targets for cryoneurolysis.

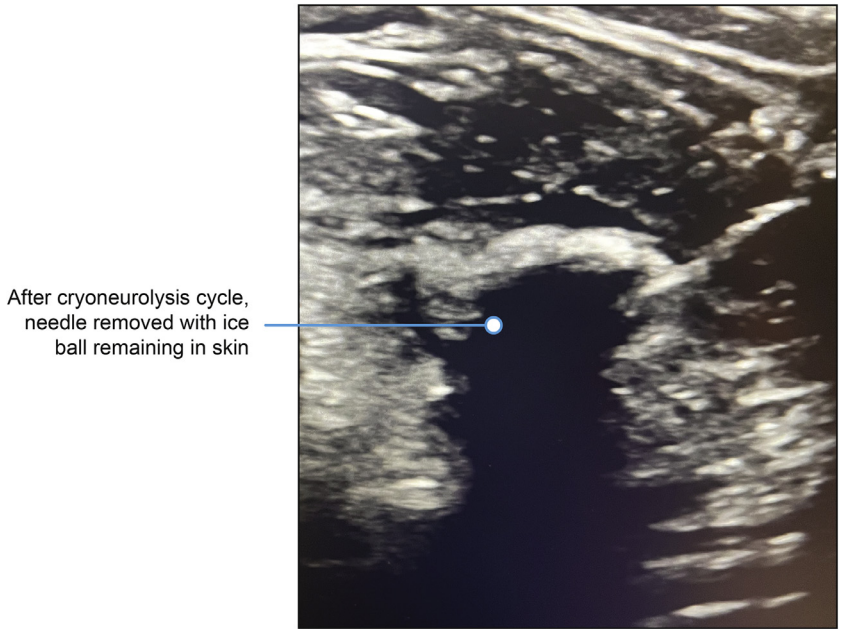

Fig 4 Ultrasound image shows the appearance of an ice ball after the cryoneurolysis procedure, following the removal of the cryoneurolysis needle (indicated by the blue dot). The human body will gradually warm the ice ball after the treatment.

medications. The patient was not interested in other options such as intrathecal baclofen or phenol management. During presentation, the patient expressed interest in a percutaneous solution. After a successful DNB to the desired nerve targets, the patient underwent cryoneurolysis of the nerves that innervated the bilateral hamstrings and gastrocnemius muscles. The patient had immediate and sustained improvement in gait. Physical therapy was resumed and then concluded 3 months later, with continued improvement in spasticity and the ability to perform multiple deadlifts.

Case 4

A 38-year-old man with spastic diparesis from cerebral palsy presented with a significant increase in baseline spasticity 1 month after total knee replacement, which caused extreme difficulty with ambulation and resulted in referral to the clinic for evaluation. The patient had a MAS score of 2 for the bilateral hamstrings and gastrocnemius with classic crouched cerebral palsy gait and a TUG test that decreased by 12 seconds from examination. The patient inquired about immediate-acting options for management to aid postsurgical rehabilitation. The patient had positive results with a DNB and underwent ultrasound-guided cryoneurolysis of the intramuscular branches of the medial/lateral gastrocnemius and medial/lateral hamstrings, with immediate change in MAS score to 1 and a return to presurgical TUG test score within 1 week. The patient went back to work within a month of the procedure.

Case 5

A 19-year-old man with spastic quadriparesis from cerebral palsy, who required total assistance with activities of daily living, presented with his caregiver for evaluation for right wrist contracture stuck at 90° involving the median nerve and the ulnar nerve below the elbow. The patient had a MAS score of 3 for the wrist flexors and appeared to be in pain from joint movement. Discussion of management options resulted in the decision to perform a DNB. After positive DNB, the patient underwent ultrasound-guided cryoneurolysis to the involved nerves. Immediately, the patient had the ability to move his wrist in a neutral position and had a score change of 1+ on MAS that was sustained at 5 months of follow-up, and his parents reported that he could tolerate splinting for longer periods.

Case 6

A 23-year-old man with mild right-sided spastic hemiparesis presented for evaluation to improve movement limited by painful spasticity and skin breakdown in the axilla because of hyperhidrosis from shoulder positioning. Examination showed a 1+ MAS score for the elbow and shoulder. The patient wanted alternatives to botulinum toxins, and a DNB was performed. After a positive nerve block, ultrasound-guided cryoneurolysis was performed to the nerve to subscapularis, lateral pectoral nerve, medial pectoral nerve, and musculocutaneous nerve to the biceps. The patient was also given a prescription for a Motus Nova interactive hand device. Immediately (at 6 weeks) and through 4 months of follow-up, the patient had no appreciable spasticity by MAS criteria, and the prior skin breakdown resolved. The patient reported improved movement in the involved proximal upper extremity because of cryoneurolysis, as well as improved dexterity from using the Motus Nova interactive hand device.

Case 7

A 17-year-old man with spastic quadriparesis from cerebral palsy presented with his family for evaluation of extreme

difficulty with access for changing the patient's diaper. The examination revealed hyperflexed knees and adductor spasticity (MAS score of 3). The patient previously lacked response to maximum-dose botulinum toxin, oral medications, splinting, and therapy, and the patient's family was not interested in phenol or pump implant. A positive DNB was performed, and ultrasound-guided cryoneurolysis was applied to the intramuscular branches of the obturator nerve to bilateral adductor magnus/longus/brevis and medial/lateral hamstring, and gastrocnemius. There was an immediate score change to 1+ on MAS of the muscles, which was sustained at 3 months, with the patient's family reporting easier ability to adduct the patient's legs for diaper changes.

Case 8

A 75-year-old woman presented with right hemiparesis after stroke, inability to walk, and resultant painful equinovarus with a MAS score of 3 for the tibial innervated muscles, especially posterior tibialis. The patient previously lacked a response to botulinum toxin, could not tolerate splinting, and had significant foot malposition pain. The patient underwent ultrasound-guided cryoneurolysis to the tibial nerve (distal to the sciatic nerve and posterior to the knee) and intramuscular posterior tibialis muscle, with an immediate MAS score change to 1+. Subsequently, the patient tolerated progressively more time splinting and, at 1 year of follow-up, did not exhibit any clinical spasticity of the tibial nerve muscles and on electromyography testing and was able to walk 200 feet walker assisted.

Case 9

A 45-year-old woman was referred to physical therapy after stroke with right spastic hemiparesis because of intractable pain limiting physical therapy participation. The patient could not tolerate multiple oral medications, had concerns with botulinum therapy, and was not a candidate for pump implantation. The patient had contracture of the shoulder/elbow and wrist, with MAS scores of 2 and 1+, respectively. Physical therapy reported that functional gains were limited because of the patient's pain. The patient elected to undergo intramuscular lidocaine nerve blocks of nerve branches to the pectoralis major/minor, biceps, brachialis, brachioradialis, pronator teres, and flexor carpi radialis. The block was successful, and the patient underwent ultrasound-guided cryoneurolysis to the aforementioned muscles with immediate improvement in pain and tightness to a MAS score of 1. At the 2- and 4-month follow-ups, the patient reported continued improvements in pain, made significant functional gains, and returned to work as a telemarketer.

Case 10

A 19-year-old man with left hemiparetic cerebral palsy presented to the clinic for evaluation of right hand and wrist contracture/pain. The patient previously lacked a response to oral medications and botulinum therapy and was not a candidate for phenol or pump implantation. The patient had a MAS score of 2 for the finger flexors, thumb, and wrist and trialed a DNB. After a successful nerve block, the patient underwent cryoneurolysis to above the elbow trunk of the median and ulnar nerves as well as the intramuscular branch to the flexor pollicis longus and flexor digitorum profundus and superficialis. Immediately, the patient had a 1-point decrease in MAS score, and the parents were able to straighten the patient's wrist and hand with much less difficulty compared with before cryoneurolysis treatment. The patient began aggressive physical therapy and used the Motus Nova hand device. After 6 months of follow-up, the patient texperienced sustained pain relief, along with some improvement in wrist and finger dexterity. The patient was also able to regularly use splints.

Discussion

Although the available treatment options for spasticity are efficacious, risks to the patient must be considered. Of these, onabotulinumtoxinA and phenol injection have the potential for distant spread causing negative effects to the respiratory system and liver, respectively. Additionally, an implanted device such as a pump has the possibility of systemic infection as well as withdrawal or overdose situations.

In recent years, cryoneurolysis has emerged as a novel treatment for pain and spasticity.[4] There are particular advantages of using cryoneurolysis as a treatment option for spasticity compared with the current classic treatment options, including preprocedure lidocaine blocks and the predictability of results that they provide. Furthermore, cryoneurolysis allows for percutaneous administration, quick access to the involved nerves, no need for an implanted device, quick improvements, and a lack of a risk profile as involved as most of the common injectate options.[5] Additional research is needed to establish cryoneurolysis treatment for spasticity beyond the presented case series.

Current medical practice provides the patient with spasticity a multitude of options for management; however, a major issue with current treatments is adverse effects. Oral medications such as baclofen are often not tolerated because of somnolence, and injectables, such as onabotulinumtoxinA and phenol, are both toxins that have the potential for distant spread with negative effects on other bodily systems. Intrathecal baclofen circumvents somnolence, but an implantable device requires strict patient adherence for success and is associated with potential withdrawal or overdose. Cryoneurolysis does not carry the potential of somnolence, distant spread, overdose, or withdrawal.

Conclusions

This case series suggests cryoneurolysis is a safe, effective, and rapid treatment option to consider in patients with spasticity. It has a favorable adverse effect profile compared with traditional injectables and baclofen pump implantation. Spasticity experts should consider cryoneurolysis in the algorithm of spasticity management.

Supplier

a. iovera°; Pacira BioSciences.

Corresponding author

Clay C. Guynn, DO, Northside Hospital, 1800 Terrace Lake Drive, Lawrenceville, GA 30043. *E-mail address:* clayguynn@gmail.com.

Disclosure

C.C.G. is a paid consultant for Pacira BioSciences, Inc.

Acknowledgments

Manuscript editing and submission support were provided by MedThink SciCom, with funding from Pacira BioSciences, Inc.

References

1. McGuire JR. Epidemiology of spasticity in the adult and child. In: Brashear A, Elovic E, eds. Spasticity: Diagnosis and management, 2nd ed., New York, NY: Demos Medical; 2016.
2. Simpson DM, Gracies JM, Graham HK, et al. Assessment: botulinum neurotoxin for the treatment of spasticity (an evidence-based review): report of the Therapeutics and Technology Assessment Subcommittee of the American Academy of Neurology. Neurology 2008;70:1691–8.
3. Rosales RL, Chua-Yap AS. Evidence-based systematic review on the efficacy and safety of botulinum toxin-A therapy in post-stroke spasticity. J Neural Transm (Vienna) 2008;115:617–23.
4. Borowski A, Littleton AG, Borkhuu B, et al. Complications of intrathecal baclofen pump therapy in pediatric patients. J Pediatr Orthop 2010;30:76–81.
5. Winston P, Mills PB, Reebye R, Vincent D. Cryoneurotomy as a percutaneous mini-invasive therapy for the treatment of the spastic limb: case presentation, review of the literature, and proposed approach for use. Arch Rehabil Res Clin Transl 2019;1:100030.
6. Ilfeld BM, Preciado J, Trescot AM. Novel cryoneurolysis device for the treatment of sensory and motor peripheral nerves. Expert Rev Med Devices 2016;13:713–25.
7. Winston P, Hashemi M, Boissonnault E, et al. Measuring the efficacy of percutaneous cryoneurolysis in the management of patients with plateaued or refractory shoulder spasticity. Arch Phys Med Rehabil 2024;105:e13.
8. Boissonnault È, MacRae F, Hashemi M, Bursuc A, Winston P. Cryoneurolysis of the femoral nerve for focal spasticity in an ambulatory patient. Arch Rehabil Res Clin Transl 2024;6:100319.
9. MacRae F, Brar A, Boissonnault E, Winston P. Cryoneurolysis of anterior and posterior divisions of the obturator nerve. Am J Phys Med Rehabil 2023;102:e1–2.
10. Winston P, Reebye R, Picelli A, David R, Boissonnault E. Recommendations for ultrasound guidance for diagnostic nerve blocks for spasticity. What are the benefits? Arch Phys Med Rehabil 2023;104:1539–48.
11. iovera HCP homepage. https://www.ioverapro.com/. Accessed November 26, 2024.